



HAL
open science

OMERACT International Consensus for Ultrasound Definitions of Tenosynovitis in Juvenile Idiopathic Arthritis: Systematic Literature Review and Delphi Process

Paz Collado, María Victoria Martire, Stefano Lanni, Orazio de Lucia, Peter Balint, Severine Guillaume-czitrom, Cristina Hernandez-diaz, Nina Krafft Sande, Silvia Magni-manzoni, Clara Malattia, et al.

► **To cite this version:**

Paz Collado, María Victoria Martire, Stefano Lanni, Orazio de Lucia, Peter Balint, et al.. OMERACT International Consensus for Ultrasound Definitions of Tenosynovitis in Juvenile Idiopathic Arthritis: Systematic Literature Review and Delphi Process. *Arthritis Care & Research = Arthritis Care and Research*, 2023, 75 (11), pp.2277-2284. 10.1002/acr.25159 . hal-04551336

HAL Id: hal-04551336








<https://hal.uvsq.fr/hal-04551336>

Submitted on 18 Apr 2024

HAL is a multi-disciplinary open access archive for the deposit and dissemination of scientific research documents, whether they are published or not. The documents may come from teaching and research institutions in France or abroad, or from public or private research centers.

L'archive ouverte pluridisciplinaire **HAL**, est destinée au dépôt et à la diffusion de documents scientifiques de niveau recherche, publiés ou non, émanant des établissements d'enseignement et de recherche français ou étrangers, des laboratoires publics ou privés.

OMERACT International Consensus for Ultrasound Definitions of Tenosynovitis in Juvenile Idiopathic Arthritis: Systematic Literature Review and Delphi Process

Paz Collado,¹  María Victoria Martire,² Stefano Lanni,³  Orazio De Lucia,⁴  Peter Balint,⁵ Severine Guillaume-Czitrom,⁶ Cristina Hernandez-Diaz,⁷ Nina Krafft Sande,⁸ Silvia Magni-Manzoni,⁹  Clara Malattia,¹⁰  Linda Rossi-Semerano,¹¹  Johannes Roth,¹² Tracy Ting,¹³ Patricia Vega-Fernandez,¹³  Daniel Windschall,¹⁴ Maria Antonietta D'Agostino,¹⁵ and Esperanza Naredo¹⁶ for the OMERACT Ultrasound Group

Objective. Synovitis and tenosynovitis are present in juvenile idiopathic arthritis (JIA), both as joint pain and/or inflammation, making them difficult to detect on physical examination. Although ultrasonography (US) allows for discrimination of the 2 entities, only definitions and scoring of synovitis in children have been established. This study was undertaken to produce consensus-based US definitions of tenosynovitis in JIA.

Methods. A systematic literature search was performed. Selection criteria included studies focused on US definition and scoring systems for tenosynovitis in children, as well as US metric properties. Through a 2-step Delphi process, a panel of international US experts developed definitions for tenosynovitis components (step 1) and validated them by testing their applicability on US images of tenosynovitis in several age groups (step 2). A 5-point Likert scale was used to rate the level of agreement.

Results. A total of 14 studies were identified. Most used the US definitions developed for adults to define tenosynovitis in children. Construct validity was reported in 86% of articles using physical examination as a comparator. Few studies reported US reliability and responsiveness in JIA. In step 1, experts reached a strong group agreement (>86%) by applying adult definitions in children after one round. After 4 rounds of step 2, the final definitions were validated on all tendons and at all locations, except for biceps tenosynovitis in children <4 years old.

Conclusion. The study shows that the definition of tenosynovitis used in adults is applicable to children with minimal modifications agreed upon through a Delphi process. Further studies are required to confirm our results.

INTRODUCTION

Juvenile idiopathic arthritis (JIA) is characterized by chronic inflammatory processes primarily targeting the synovial tissue of joints and tendon sheaths. The gold standard for synovitis detection has traditionally been the clinical assessment of swollen joints

by physicians. However, distinguishing tenosynovitis from underlying synovitis, an abnormality which can also be present, may be challenging based only on clinical examination, especially for small joints (1,2). Understanding the exact location of inflammation is crucial to optimize therapeutic decision-making, particularly

¹Paz Collado, MD, PhD: Hospital Universitario Severo Ochoa and Universidad Internacional Alfonso X El Sabio, Madrid, Spain; ²María Victoria Martire, MD: Hospital San Roque de Gonnet, La Plata, Buenos Aires, Argentina; ³Stefano Lanni, MD: Fondazione IRCCS Ca' Granda Ospedale Maggiore Policlinico, Milan, Italy; ⁴Orazio De Lucia, MD: ASST Centro Traumatologico Ortopedico G. Pini-CTO, Milan, Italy; ⁵Peter Balint, MD, PhD: National Institute of Musculoskeletal Diseases, Budapest, Hungary; ⁶Severine Guillaume-Czitrom, MD: University Hospital of Bicêtre, APHP Le Kremlin-Bicêtre, France; ⁷Cristina Hernandez-Diaz, MD: Instituto Nacional de Rehabilitación Luis Guillermo Ibarra and Hospital Juárez de México, Ciudad de México, Mexico; ⁸Nina Krafft Sande, MD: Oslo University Hospital, Oslo, Norway; ⁹Silvia Magni-Manzoni, MD, PhD: IRCCS Bambino Gesù Children's Hospital, Rome, Italy; ¹⁰Clara Malattia, MD, PhD: UOC Clinica Pediatrica e Reumatologia, IRCCS Istituto Giannina Gaslini, and University of Genoa, Genoa, Italy; ¹¹Linda Rossi-Semerano, MD: Centre Hospitalier Universitaire de Bicêtre, APHP, National Reference Centre for Auto-Inflammatory Diseases and Amyloidosis of Inflammatory origin, Le Kremlin-Bicêtre, France; ¹²Johannes Roth,

MD, PhD: Children's Hospital of Eastern Ontario, Ottawa, Ontario, Canada; ¹³Tracy Ting, MD, Patricia Vega-Fernandez, MD: Cincinnati Children's Hospital Medical Center and University of Cincinnati, Cincinnati, Ohio; ¹⁴Daniel Windschall, MD: Clinic of Paediatric and Adolescent Rheumatology, St.-Josef-Stift Sendenhorst, Northwest German Center for Rheumatology, Sendenhorst, Germany, and Martin-Luther-University Halle-Wittenberg, Halle, Germany; ¹⁵Maria Antonietta D'Agostino, MD, PhD: Fondazione Policlinico Universitario Agostino Gemelli IRCCS and Università Cattolica del Sacro Cuore, Rome, Italy; ¹⁶Esperanza Naredo, MD, PhD: Hospital General Universitario Gregorio Marañón and Universidad Autónoma de Madrid, Madrid, Spain.

Author disclosures are available online at <https://onlinelibrary.wiley.com/doi/10.1002/acr.25159>.

Address correspondence via email to Paz Collado, MD, PhD, at paxko10@gmail.com.

Submitted for publication February 28, 2023; accepted in revised form May 16, 2023.

SIGNIFICANCE & INNOVATIONS

- Musculoskeletal ultrasonography (US) is an important tool in the assessment of disease activity in childhood arthritis.
- To assess disease activity, precise definitions for different pathologic findings are an essential prerequisite for the reliable use of this technology in the pediatric ages.
- To date, the pediatric subgroup of the Outcome Measures in Rheumatology US Working Group has completed validation processes for US definitions of normal joint components and synovitis. Now, US definitions for tenosynovitis in children have just been developed and validated through an international consensus process.

for local injections. Musculoskeletal ultrasonography (US) provides an objective assessment of inflammation in peripheral joints (3). US is a versatile, multiplanar, and inexpensive bedside imaging modality with high patient acceptability, and provides direct visualization for local steroid injections (4,5).

With the advent of the treat-to-target concept and the availability of novel therapies, objective and sensitive monitoring of treatment efficacy is of utmost importance. In this perspective validated study, US definitions of elementary lesion components of synovitis and tenosynovitis represent a useful adjunct to clinical practice.

The Outcome Measures in Rheumatology (OMERACT) US Pediatric subgroup was formed to standardize the use of US in JIA. To date, US definitions for normal joint components and for synovitis have been developed (6,7,8). The JIA subgroup of the OMERACT US Working Group has recently completed a validation process for tenosynovitis according to the OMERACT Filter 2.1 Instrument Selection Algorithm (OFISA) (9). The purpose of this study was to define and validate the definition of the elementary lesions of US tenosynovitis in children with JIA.

MATERIALS AND METHODS

Study design. The study consisted of 2 phases: 1) a systematic literature review focused on the identification of studies on US as an outcome measure for the diagnosis and monitoring of tenosynovitis in children with JIA, and 2) a consensus process to develop and validate definitions for the elementary lesions of tenosynovitis in children.

Systematic literature review: search strategy, study selection, and data extraction. We searched in 3 databases (PubMed, Embase, and Cochrane) from their inceptions to September 1, 2022, for studies that assessed tenosynovitis in children <18 years old with JIA. We followed the Patient/Population, Intervention, Comparison, and Outcomes methodology

(musculoskeletal ultrasound [US], comparison: other imaging techniques; and outcomes: diagnosis of tenosynovitis) to define the setting.

The search strategy included the following combination of subject headings and search terms: “ultrasonography,” “echography,” “Doppler,” “juvenile idiopathic arthritis,” “juvenile arthritis,” “tenosynovitis,” “tendinopathy,” “diagnosis,” “follow-up,” “therapy management.” To ensure completeness of the search, a manual review of the references of included studies was performed. However, no studies were found through this additional review. The limits used were original articles, English language, humans only, and subjects ≤18 years old. Exclusion criteria consisted of 1) reviews, editorials, letters, case reports, and abstracts of scientific congresses; and 2) studies with a mixed patient population (i.e., adult and children). Review of studies for inclusion was conducted by 2 separate authors (PC and VM) and a third author (EN) was appointed to resolve any discrepancies.

Data were extracted from articles fulfilling the selection criteria, with particular focus on the definition used, scoring system applied, and the metric properties of US evaluated. Data were then recorded using a predetermined form that was previously designed (10) for this purpose. Extracted data included author, publication year, study design, JIA subtype, number of patients and controls, tendons examined, definitions of US tenosynovitis in children with JIA (if present), the global description of the US technique, the US mode used (i.e., B-mode/grayscale alone, Doppler mode alone, or a combination of both), and the scoring systems used for the scanned tendons: 1) binary (yes/no) for the presence of synovial hypertrophy or effusion or power Doppler alone in the tendon sheath, or 2) semiquantitative. Information about the construct and criterion validity, reliability, and discriminant validity of US was also recorded. Each included study was analyzed to determine whether the measurement properties of US fulfilled the criteria according to the OFISA (9).

Systematic literature review: quality assessment of included studies.

To analyze the study quality, the same methodology as in a previous systematic literature review of synovitis in JIA was used (11). It included a set of 6 predefined criteria: 1) was the recruitment of patients well-defined in the methods section; 2) was there a description of normal US anatomy of pediatric tendons; 3) was there a description of the US scanning technique (settings used, type of machine and protocol of scanning); 4) was there a description of the blinding attempted for observers; 5) was there a description of US tenosynovitis and the scoring system mentioned; and 6) was the comparator adequately explained (baseline and/or follow-up) and the results presented in their entirety? Quality was reported on a scale of 0–6, with higher results indicating higher quality.

Consensus process. A 2-step consensus process on US-defined tenosynovitis in children was carried out to develop the definitions (step 1) as well as to validate them by testing their applicability on US images representing various degrees of tenosynovitis in various age groups (step 2).

In the first step, based on the information obtained from the systematic literature review, the preliminary proposal was to evaluate whether the consensus definitions developed and used in adults with rheumatoid arthritis (RA) would be suitable for children with JIA (12). A questionnaire based on the statements developed for RA (12) was sent to a panel of 37 international experts in pediatric musculoskeletal US from 14 countries that are part of the OMERACT US group. The participants were asked to rate their level of agreement with each statement on a 5-point Likert scale (1 = strongly disagree; 5 = strongly agree). Agreement was achieved if ≥80% of responders scored a statement as either 4 or 5. Additionally, comments were allowed at the end of each statement.

The aim of the second step was to validate each statement (i.e., normal tendon structure, normal tendon synovial

sheath, normal retinaculum and finger flexor pulley, tendon sheath effusion, tenosynovial hypertrophy, and US definitions of tenosynovitis on both B-mode and power Doppler) by testing their applicability on US images showing tenosynovitis in children from JIA patients at various ages. A total of 18 task force members, who participated actively in the previous task, were instructed to acquire standardized US images according to the literature (13). Tendons often involved in JIA were preselected (biceps, hand, wrist, and ankle tendons). The participants collected at least 1 B-mode and power Doppler image per tendon, representative of tenosynovitis, in both transverse and longitudinal planes. Additionally, they indicated the age group (toddler and preschool ages 2–4 years, young children ages 5–8 years, preadolescent ages 9–12 years, and teenager ages 13–16 years) in the saved image as agreed upon in a previous exercise (13). Only anonymized images were used. Participating centers did not require ethics approval for this web-based exercise. The US equipment used for image collection differed from one participating center to another.

Table 1. Description of the studies reporting ultrasound validity in the assessment of tenosynovitis in juvenile idiopathic arthritis*

| Author, year (ref.) | Study type | No. of patients | No. of patients in control group | Joint region | Tendon assessed | Reliability | Quality score |
|---------------------------------|------------|-----------------|----------------------------------|---|---|---------------------------------|---------------|
| Karmazyn et al, 2007 (15) | CS | 20 | 12 | MCP | FFT | NA | 6 |
| Magni-Manzoni et al, 2009 (16) | CS | 32 | 0 | Elbow,wrist, IP, MCP, knee, ankle, toes | NA | NA | 2 |
| Rooney et al, 2009 (1) | CS | 34 | 0 | Ankle | TPT, PT | NA | 2 |
| Pascoli et al, 2010 (2) | CS | 42 | 0 | Ankle | TPT, PT | Interobserver | 2 |
| Laurell et al, 2011 (4)† | PL | 30 | 0 | Ankle | TPT, PT, FDL, FHL, TA, EHL, EDL | NA | 3 |
| Laurell et al, 2012 (5)† | PL | 11 | 0 | Wrist | APL, EPB, ECR, EPL, EDC, EDM, ECU, FCR, FDD | NA | 5 |
| Hendry et al, 2012 (17) | CS‡ | 30 | 0 | Ankle, IP, MTP | TPT, PT, FDL, FHL | NA | 3 |
| Magni-Manzoni et al, 2013 (18) | PL | 39 | 39 | Elbow, wrist, IP, MCP, knee, ankle, toes | Not specified | NA | 5 |
| Collado et al, 2014 (19) | CS | 34 | 0 | Shoulder, elbow, wrist, MCP, hand, IP, knee, ankle, MTP | EDC, FFT, TFT | Interobserver | 5 |
| Peters et al, 2017 (20) | CS | 244 | 0 | Ankle, wrist | TPT, PT, FDL TA, FHL, APL, EPB, ECR, EPL, EDC, TFT, FFT, BT | NA | 2 |
| Ventura-Ríos et al, 2018 (3) | CS | 30 | 0 | Wrist, 2MCP, 3MCP | EDC, FFT | Interobserver/ intraobserver | 5 |
| Lanni et al, 2021 (21) | CS | 78 | 0 | Ankle | TA, EDL, FDL, PT, EHL, TPT, FHL | NA | 4 |
| Collado et al, 2022 (22) | CS | 28 | 54 | Ankle | TA, EHL, EDL, TPT, FDL, FHL, PT | NA | 5 |
| Della Paolera et al, 2022 (23)† | CS | 48 | 0 | Ankle | TPT, PT, FDL, FHL, EDL, EHL | NA | 2 |

* The comparator used for construct validity was clinical examination in all studies except Peters et al (ref. 20), in which a comparator was not available. APL = abductor pollicis longus; BT = biceps tendons; CS = cross-sectional; ECU = extensor carpi ulnaris; ECR = extensor carpi radialis; EDC = extensor digitorum communis; EDL = extensor digitorum longus; EDM = extensor digit minimi; EHL = extensor hallucis longus; EPB = extensor pollicis brevis; EPL = extensor pollicis longus; FCR = Flexor carpi radialis; FDD = flexor digitorum superficialis and profundus; FDL = flexor digitorum longus; FFT = finger flexor tendon; FHL = flexor hallucis longus; FPL = flexor pollicis longus; IP = interphalangeal; MCP = metacarpophalangeal; MTP = metatarsophalangeal joint; NA = not available; PL = prospective longitudinal; PT = peroneal tendons; TA = tibialis anterior; TFT = toe flexor tendon; TPT = tibialis posterior tendon.

† Sensitivity to change was measured in the indicated study.

‡ Cross-sectional (CS) here indicates a section of a phase II randomized controlled trial, the Foot Arthritis trial.

The convenor (PC) collected images from the participants and sent them back a representative selection, asking to assess each image and rate applicability of statements using a 5-point Likert scale. An agreement of $\geq 70\%$ was considered mandatory for consensus. The answers from each round of the questionnaire that did not reach the agreement threshold were revised and modified according to the experts' comments, then resent to the panel for the next round until agreement was reached for all statements. Similarly, images not reaching the agreement threshold were replaced with new images provided by the participants.

Statistical analysis. Descriptive statistics were calculated from the responses to the questionnaires. The results from the Delphi process were presented as the percentage of responders who scored a statement as either 4 or 5.

RESULTS

Systematic literature review process. The study selection process is shown in a Preferred Reporting Items for Systematic reviews and Meta-Analysis flow diagram (14) (Supplementary

Figure 1, available on the *Arthritis Care & Research* website at <http://onlinelibrary.wiley.com/doi/10.1002/acr.25159/abstract>).

Summary of included studies. The features and metric properties of the 14 studies included in the systematic literature review are shown in Tables 1 and 2 (1–5, 15–23). The main objective in most studies was the assessment of synovitis, whereas tenosynovitis was the second objective. The designs of the studies are shown in Table 1; the majority of which were cross-sectional (15–16, 19–23). The number of patients included in each study was relatively small (range 11–42), except for 2 that included 78 and 244 patients, respectively (20, 21). There were only 3 studies that included a control group (15, 18, 22). The ankle tendons were most studied (11 of 14 [78%]), particularly the posterior tibialis (1, 2, 4, 18–23), while the biceps tendon was rarely investigated (20).

US definitions and scoring systems of tenosynovitis in children reported are shown in Table 2. Most articles (1–5, 17, 19, 21) included the US definitions for adult RA to define tenosynovitis in children (24), and a tenosynovitis scoring system was included in 9 articles (64%). Different machine brands and frequencies of the transducers were used (from 5–20 MHz) (Table 2). Except for

Table 2. US definition and description of tenosynovitis or its elementary components evaluated and correlating tenosynovitis scoring systems*

| Author, year (ref.) | Definition of tenosynovitis included in the study | Scoring system | Equipment (Doppler setting) |
|--------------------------------|---|-----------------------|--|
| Karmazyn et al, 2007 (15) | “Fluid and vascularity within TS” | Semiquantitative (CD) | Philips 5000 (CD: 1.7–2.5 cm/second; maximized gain levels until color noise was outside the vessel wall) |
| Magni-Manzoni et al, 2009 (16) | OMERACT† | Binary | GE Logiq 9 |
| Rooney et al, 2009 (1) | OMERACT† | NA | SonoSite 180 Plus or Esaote MyLab 25 |
| Pascoli et al, 2010 (2) | OMERACT† | NA | Esaote MyLab 25 (PRF 700 Hz, LF, highest gain not displaying background artefact) |
| Laurell et al, 2011 (4) | OMERACT† | NA | GE Logiq 9 (PRF 600 Hz, LF, color gain just below the level at which noise appeared) |
| Laurell et al, 2012 (5) | OMERACT† | NA | GE Logiq 9 (PRF 600 Hz, LF, color gain just below the level at which noise appeared) |
| Hendry et al, 2012 (17) | OMERACT† | Binary | Siemens Acuson Antares |
| Magni-Manzoni et al, 2013 (18) | OMERACT† | Binary | GE Logiq 9 |
| Collado et al, 2014 (19) | OMERACT† | Binary | GE Logiq E (PRF 600 Hz, LF, highest PD gain not showing signal under the bony cortex) |
| Peters et al, 2017 (20) | “TS thickening with echogenic fluid, increased CD signal, or a combination” | Binary | NA |
| Ventura-Ríos et al, 2018 (3) | OMERACT† | NA | GE Logiq E R6 (PRF 500 Hz, LF, highest gain not showing signal under the bony cortex) |
| Lanni et al, 2021 (21) | “The presence of swelling in the related tendon area” | Binary | Esaote MyLab alpha (PRF 480–700 Hz, LF, highest gain just below the level not displaying color noise in the underlying bone) |
| Collado et al, 2022 (22) | “Abnormal TS thickening with or without PD” | Binary | GE Logiq E (PRF 600 Hz, LF, gain was adjusted until the background signal was removed) |
| Della Paolera et al, 2022 (23) | “Thickened TS with fluid, Doppler signal may be present” | Binary | NA |

* Doppler imaging was used in all studies except in Peters et al, 2017 (ref. 20). CD = color Doppler; LF = lowest filter; NA = not applicable; PD = power Doppler; PRF = pulse repetition frequency; TS = tendon sheath.

† The Outcome Measures in Rheumatology Clinical Trials (OMERACT) definitions for ultrasound (US) tenosynovitis in adults (ref. 24).

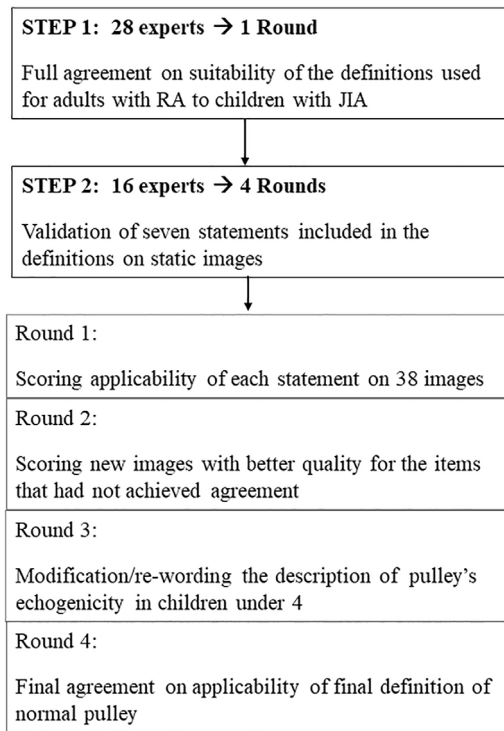


Figure 1. Workflow showing the consensus process to develop and validate the definitions of tenosynovitis in children (step 1 and step 2). JIA = juvenile idiopathic arthritis; RA = rheumatoid arthritis.

2 articles, all studies included power Doppler mode, but only 8 detailed the settings (2–5, 15, 19, 21, 22).

The metric properties of the studies are shown in Tables 1 and 2. Construct validity was the most common aspect of US validity reported, which included clinical examination and patient-reported outcome measures as comparators in 12 and 6 studies, respectively. Overall, the results of those studies show that US detected tenosynovitis more often than clinical examination (Supplementary Table 1, available at <http://onlinelibrary.wiley.com/doi/10.1002/acr.25159/abstract>). Criterion validity of US in relation to histology was not studied. The study by Karmazyn et al was the only one that described a scoring system for Doppler mode (15). The reliability and ability of US to detect changes over time in JIA were reported in 3 studies (2, 3, 19) and in 3 other studies, respectively (4, 5, 23).

Quality assessment of included studies. Quality scores are shown in Table 1 (Detailed scores are shown in Supplementary Table 1, available at <http://onlinelibrary.wiley.com/doi/10.1002/acr.25159/abstract>). Of the 14 studies selected, only 6 achieved a minimum quality score ≥4 (3, 5, 15, 18, 19, 22).

Consensus process findings. The workflow of the consensus process to develop and validate definitions on static images is shown in Figure 1.

First step. A total of 28 of 37 participants responded to the first questionnaire (75% response rate). For all statements group agreement was ≥86% in the first round.

Second step. Once group agreement was reached in step 1, 7 statements related to the consensus definitions in adults with RA were validated in a 4-round web-based exercise testing its applicability in tenosynovitis in children. A total of 18 experts were invited, of whom 16 (89%) participated in all rounds.

For the first and the second rounds, a set of 38 US images were assessed by the participants who rated their agreement on applicability of each statement. The 7 statements reached a strong group agreement for the ankle tendons for all age groups (range 80–100%) in the first round, but there was no agreement for the remaining tendons. The second round provided new images for the items that had not achieved agreement. Except for the normal pulley in the youngest children, group agreement was reached for the tendons of the wrist (73–100%) and the finger (73–100%). Despite the ability of US to display the normal finger pulleys at the level of metacarpophalangeal joints in children, some comments were raised about the pulley’s echogenicity in young children after evaluating the images in the second round. The percentage of group agreement per statement after the second round is shown in Table 3.

For the third round, the description of a normal pulley was reworded as follows: “a linear hyperechoic structure, although it could artifactually appear hypoechoic.” This modification achieved a strong group agreement (99.8%) in the fourth and final round.

Table 3. Group agreement for tenosynovitis definition at different ages in various joints*

| Age, years | Definition per each statement | | | | | | |
|-----------------|-------------------------------|-----|-----|-----|-----|-----|-----|
| | 1 | 2 | 3 | 4 | 5 | 6 | 7 |
| Shoulder | | | | | | | |
| 2–4 years | 100 | 86 | NA | 56 | 60 | 62 | 56 |
| 5–8 years | 86 | 86 | NA | 77 | 100 | 100 | 93 |
| 9–12 years | 86 | 80 | NA | 71 | 71 | 80 | 80 |
| 13–15 years | 94 | 88 | NA | 93 | 93 | 100 | 93 |
| Wrist | | | | | | | |
| 2–4 years | 93 | 100 | 75 | 86 | 93 | 100 | 100 |
| 5–8 years | 100 | 71 | 100 | 100 | 100 | 100 | 100 |
| 9–12 years | 86 | 75 | 73 | 80 | 93 | 100 | 93 |
| 13–15 years | 86 | 93 | 86 | 73 | 86 | 100 | 100 |
| Finger | | | | | | | |
| 2–4 years | 87 | 73 | 68 | 100 | 93 | 73 | 75 |
| 5–8 years | 80 | 80 | 67 | 93 | 100 | 100 | 93 |
| 9–12 years | 73 | 73 | 87 | 87 | 100 | 100 | 100 |
| 13–15 years | 93 | 93 | 87 | 93 | 73 | 93 | 73 |
| Ankle | | | | | | | |
| 2–4 years | 87 | 73 | 78 | 100 | 93 | 100 | 100 |
| 5–8 years | 87 | 80 | 80 | 86 | 86 | 93 | 93 |
| 9–12 years | 87 | 80 | 80 | 86 | 100 | 100 | 100 |
| 13–15 years | 87 | 80 | 80 | 100 | 87 | 100 | 93 |

* Values are the percentage of answers that scored grade 4 or 5 for each of the images on a 5-point Likert scale in the second round.

Table 4. Description of the final validated US definitions*

| Statement | Definition |
|--|--|
| Normal structure; tendon (definition 1) | Hyperechoic (relative to subdermal fat) fibrillar pattern (i.e., hyperechoic parallel lines in long plane and hyperechoic dots in transverse plane) |
| Normal structure; tendon synovial sheath (definition 2) | A thin regular hypoechoic (relative to tendon fibers) halo surrounding (in transverse plane), thin regular hypoechoic lines above and below the tendon structure (in long plane) at anatomical sites where synovial sheaths are known to exist and which can be distinguished from pulleys and retinaculae |
| Normal structure; retinaculum (wrist and ankle level) and pulleys (finger flexor level) (definition 3) | Annular pulley appeared as a focal hyperechoic (or hypoechoic depending on the US insonation angle) fibrillar structure relative to the adjacent flexor tendon that can be detected overlying the parietal synovial sheath of the digital flexor tendon at its expected anatomical location |
| Elementary lesion; tendon sheath effusion (definition 4) | Presence of abnormal anechoic or hypoechoic (relative to tendon fibers) material within the synovial sheath, either localized (e.g., in the synovial sheath cul-de-sacs) or surrounding the tendon that is displaceable and seen in 2 perpendicular planes |
| Elementary lesion; tenosynovial hypertrophy (definition 5) | Presence of abnormal hypoechoic (relative to tendon fibers) tissue within the synovial sheath that is not displaceable and poorly compressible and seen in 2 perpendicular planes |
| Tenosynovitis on B-mode (definition 6) | Abnormal anechoic or hypoechoic (relative to tendon fibers) tendon sheath widening, which can be related to both the presence of tenosynovial abnormal effusion or hypertrophy |
| Tenosynovitis on Doppler (definition 7) | The presence of peritendinous Doppler signal within the synovial sheath, seen in 2 perpendicular planes, excluding normal feeding vessels (i.e., vessels at the mesotenon or vincula) only if the tendon shows peritendinous synovial sheath widening on B-mode |

* US = ultrasound.

After 4 rounds, the final definitions were validated on all tendons and at all locations, except for biceps tenosynovitis in children <4 years old, which showed no agreement regarding its applicability, due to a lack of images available for this location and age group. The final version of the validated US definitions for elementary lesions in tenosynovitis in children is shown in Table 4. An US image illustrating

some of these lesions that correspond to the definition is shown in Figure 2.

DISCUSSION

Definitions for the US appearance of tenosynovitis in children were developed through a consensus process and validated in web-based exercises. This study is an important step toward a more reliable use of musculoskeletal US in children as an outcome measure of disease activity (25).

Consistent with the previous systematic literature review on synovitis (11), US examination of the foot and hand remains a priority in JIA, given the frequency of involvement and the challenges of the clinical assessment (1,2,18,22). In contrast, biceps tendon involvement is less well studied, since inflammation affecting the shoulder joint or tendons is less reported in children compared to adults. Like the systematic literature review of synovitis, the current systematic literature review showed a moderate quality of existing studies illustrating a need for ongoing research on the validity of US in tenosynovitis in children.

As reflected in the systematic literature review, the absence of definitions of tenosynovitis in children for JIA over the years has led several authors to use existing definitions that were developed for adults (24). However, their applicability to children might require some considerations. To address this issue, the OMERACT US Working Group has conducted the current Delphi process. The group unanimously agreed that the definitions used in adults can be applied in the pediatric population in the first round of step 1. In step 2, instead of a de novo development of definitions, the adult definitions were assessed for their suitability in children on static images. The final definitions for tenosynovitis in children were validated for all tendons and ages, except biceps

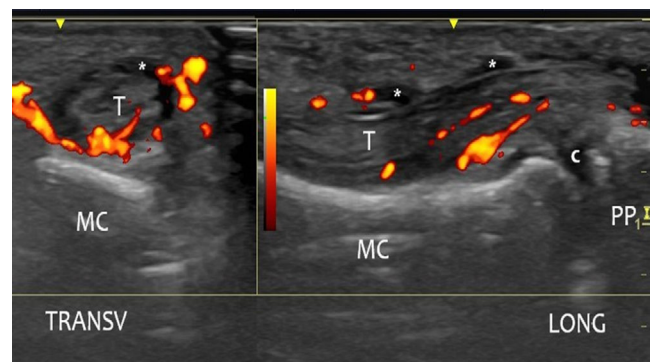


Figure 2. Tenosynovitis on Doppler ultrasound imaging of the finger of a 6-year-old child. The image shows the presence of tendon sheath effusion (*) and peritendinous Doppler signal within the synovial sheath in the flexor tendon of the second finger, seen in 2 perpendicular planes. c = unossified hyaline cartilage of the secondary ossification nucleus of the phalanx; MC = metacarpal bone; PP = proximal phalanx; T = tendon.

tenosynovitis in children ages 2–4 years, since no images of tenosynovitis were available for this location and age group. This may reflect limited involvement of the shoulder in JIA but may also indicate that this is an understudied area.

A group agreement for the US-defined normal finger pulley in children <8 years old was reached after 4 rounds. It highlights the difficulty to clearly distinguish this structure in healthy children, even on high-quality images, or the fact that pulleys became more detectable on US in children who are engaged in physical activities like rock climbing, which often increases visibility of pulleys due to changes in the supporting structures of the hands and fingers (26–29). Some limitations should be noted; we validated the US definition of tenosynovitis in children only on static images, and most participants were experts in US. However, performing an international validation study in children in real time is a challenge because it is not feasible to gather children grouped by age to be scanned several times by different sonographers in a day.

Although children differ significantly from adults in their bone anatomy (mostly related to maturation of bones), the present study demonstrated that the definitions of tenosynovitis used in adults are applicable to children with minimal modifications determined through a Delphi process. Further studies are required to confirm our results as well as to evaluate metric properties of US in the assessment of tenosynovitis in children with JIA.

AUTHOR CONTRIBUTIONS

All authors were involved in drafting the article or revising it critically for important intellectual content, and all authors approved the final version to be submitted for publication. Dr. Collado had full access to all of the data in the study and takes responsibility for the integrity of the data and the accuracy of the data analysis.

Study conception and design. Collado, D’Agostino, Naredo.

Acquisition of data. Collado, Martire, Lanni, De Lucia, Balint, Guillaume-Czitrom, Hernandez-Diaz, Sande, Magni-Manzoni, Malattia, Rossi-Semerano, Roth, Ting, Vega-Fernandez, Windschall, D’Agostino, Naredo.

Analysis and interpretation of data. Collado, Martire, Lanni, De Lucia, Balint, Guillaume-Czitrom, Hernandez-Diaz, Sande, Magni-Manzoni, Malattia, Rossi-Semerano, Roth, Ting, Vega-Fernandez, Windschall, D’Agostino, Naredo.

REFERENCES

1. Rooney ME, McAllister C, Burns JF. Ankle disease in juvenile idiopathic arthritis: ultrasound findings in clinically swollen ankles. *J Rheumatol* 2009;36:1725–9.
2. Pascoli L, Wright S, McAllister C, et al. Prospective evaluation of clinical and ultrasound findings in ankle disease in juvenile idiopathic arthritis: importance of ankle ultrasound. *J Rheumatol* 2010;37:2409–14.
3. Ventura-Ríos L, Faugier E, Barzola L, et al. Reliability of ultrasonography to detect inflammatory lesions and structural damage in juvenile idiopathic arthritis. *Pediatr Rheumatol Online J* 2018;16:58.
4. Laurrell L, Court-Payen M, Nielsen S, et al. Ultrasonography and color Doppler in juvenile idiopathic arthritis: diagnosis and follow-up of ultrasound-guided steroid injection in the ankle region. A descriptive interventional study. *Pediatr Rheumatol Online J* 2011;9:4.

5. Laurrell L, Court-Payen M, Nielsen S, et al. Ultrasonography and color Doppler in juvenile idiopathic arthritis: diagnosis and follow-up of ultrasound guided steroid injection in the wrist region. A descriptive interventional study. *Pediatr Rheumatol J* 2012;10:11.
6. Roth J, Jousse-Joulin S, Magni-Manzoni S, et al. Definitions for the sonographic features of joints in healthy children. *Arthritis Care Res (Hoboken)* 2015;67:136–42.
7. Collado P, Windschall D, Vojinovic J, et al. Amendment of the OMERACT ultrasound definitions of joints’ features in healthy children when using the DOPPLER technique. *Pediatr Rheumatol Online J* 2018;16:23.
8. Roth J, Ravagnani V, Backhaus M, et al. Preliminary definitions for the sonographic features of Synovitis in children. *Arthritis Care Res (Hoboken)* 2017;69:1217–23.
9. Outcome Measures in Rheumatology. The OMERACT handbook. URL: <https://omeracthandbook.org/handbook>.
10. Joshua F, Lassere M, Bruyn GA, et al. Summary findings of a systematic review of the ultrasound assessment of synovitis [review]. *J Rheumatol* 2007;34:839–47.
11. Collado P, Jousse-Joulin S, Alcalde M, et al. Is ultrasound a validated imaging tool for the diagnosis and management of synovitis in juvenile idiopathic arthritis? A systematic literature review [review]. *Arthritis Care Res (Hoboken)* 2012;64:1011–9.
12. Naredo E, D’Agostino MA, Wakefield R, et al. Reliability of a consensus-based ultrasound score for tenosynovitis in rheumatoid arthritis. *Ann Rheum Dis* 2013;72:1328–34.
13. Collado P, Vojinovic J, Nieto JC, et al. Toward standardized musculoskeletal ultrasound in pediatric rheumatology: normal age-related ultrasound findings. *Arthritis Care Res (Hoboken)* 2016;68:348–56.
14. Page MJ, McKenzie JE, Bossuyt PM, et al. The PRISMA 2020 statement: an updated guideline for reporting systematic reviews. *BMJ* 2021;372:n71.
15. Karmazyn B, Bowyer SL, Schmidt KM, et al. US findings of metacarpophalangeal joints in children with idiopathic juvenile arthritis. *Pediatr Radiol* 2007;37:475–82.
16. Magni-Manzoni S, Epis O, Ravelli A, et al. Comparison of clinical versus ultrasound-determined synovitis in juvenile idiopathic arthritis. *Arthritis Rheum* 2009;61:1497–504.
17. Hendry GJ, Gardner-Medwin J, Steultjens MP, et al. Frequent discordance between clinical and musculoskeletal ultrasound examinations of foot disease in juvenile idiopathic arthritis. *Arthritis Care Res (Hoboken)* 2012;64:441–7.
18. Magni-Manzoni S, Scirè CA, Ravelli A, et al. Ultrasound-detected synovial abnormalities are frequent in clinically inactive juvenile idiopathic arthritis, but do not predict a flare of synovitis. *Ann Rheum Dis* 2013;72:223–8.
19. Collado P, Gamir ML, Lopez-Robledillo JC, et al. Detection of synovitis by ultrasonography in clinically inactive juvenile idiopathic arthritis on and off medication. *Clin Exp Rheumatol* 2014;32:597–603.
20. Peters SE, Laxer RM, Connolly BL, et al. Ultrasound-guided steroid tendon sheath injections in juvenile idiopathic arthritis: a 10-year single-center retrospective study. *Pediatr Rheumatol Online J* 2017;15:22.
21. Lanni S, Marafon DP, Civino A, et al. Comparison between clinical and ultrasound assessment of the ankle region in children with juvenile idiopathic arthritis. *Arthritis Care Res (Hoboken)* 2021;73:1180–6.
22. Collado P, González-Fernández ML. The pediatric foot: prevalence and differentiation of sonographic and podiatric findings in juvenile arthritis and healthy children. *Clin Exp Rheumatol* 2022;40:655–61.
23. Della Paolera S, Pastore S, Zabotti A, et al. Ultrasonographic assessment for tenosynovitis in juvenile idiopathic arthritis with ankle involvement: diagnostic and therapeutic significance. *Children (Basel)* 2022;9:509.

24. Wakefield RJ, Balint PV, Szkudlarek M, et al. Musculoskeletal ultrasound including definitions for ultrasonographic pathology. *J Rheumatol* 2005;32:2485–7.
25. Colebatch-Bourn AN, Edwards CJ, Collado P, et al. EULAR-PRoS points to consider for the use of imaging in the diagnosis and management of juvenile idiopathic arthritis in clinical practice [review]. *Ann Rheum Dis* 2015;74:1946–57.
26. Cohen MJ, Kaplan L. Histology and ultrastructure of the human flexor tendon sheath *J Hand Surg Am* 1987;12A:25–9.
27. Doyle JR. Palmar and digital flexor tendon pulleys [review]. *Clin Orthop Relat Res* 2001;383:84–96.
28. Hauger O, Chung CB, Lektrakul N, et al. Pulley system in the fingers: normal anatomy and simulated lesions in cadavers at MR imaging, CT, and US with and without contrast material distention of the tendon sheath. *Radiology* 2000;217:201–12.
29. Boutry N, Titéca M, Demondion X, et al. High-frequency ultrasonographic examination of the finger pulley system. *J Ultrasound Med* 2005;24:1333–9.